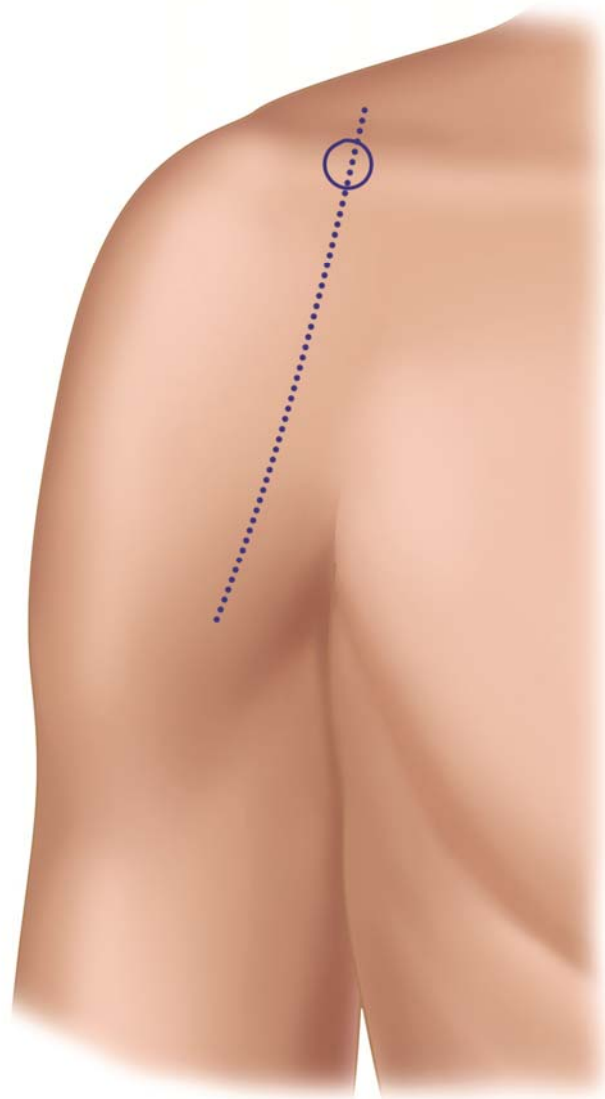


# SURGICAL PAIN CONSORTIUM

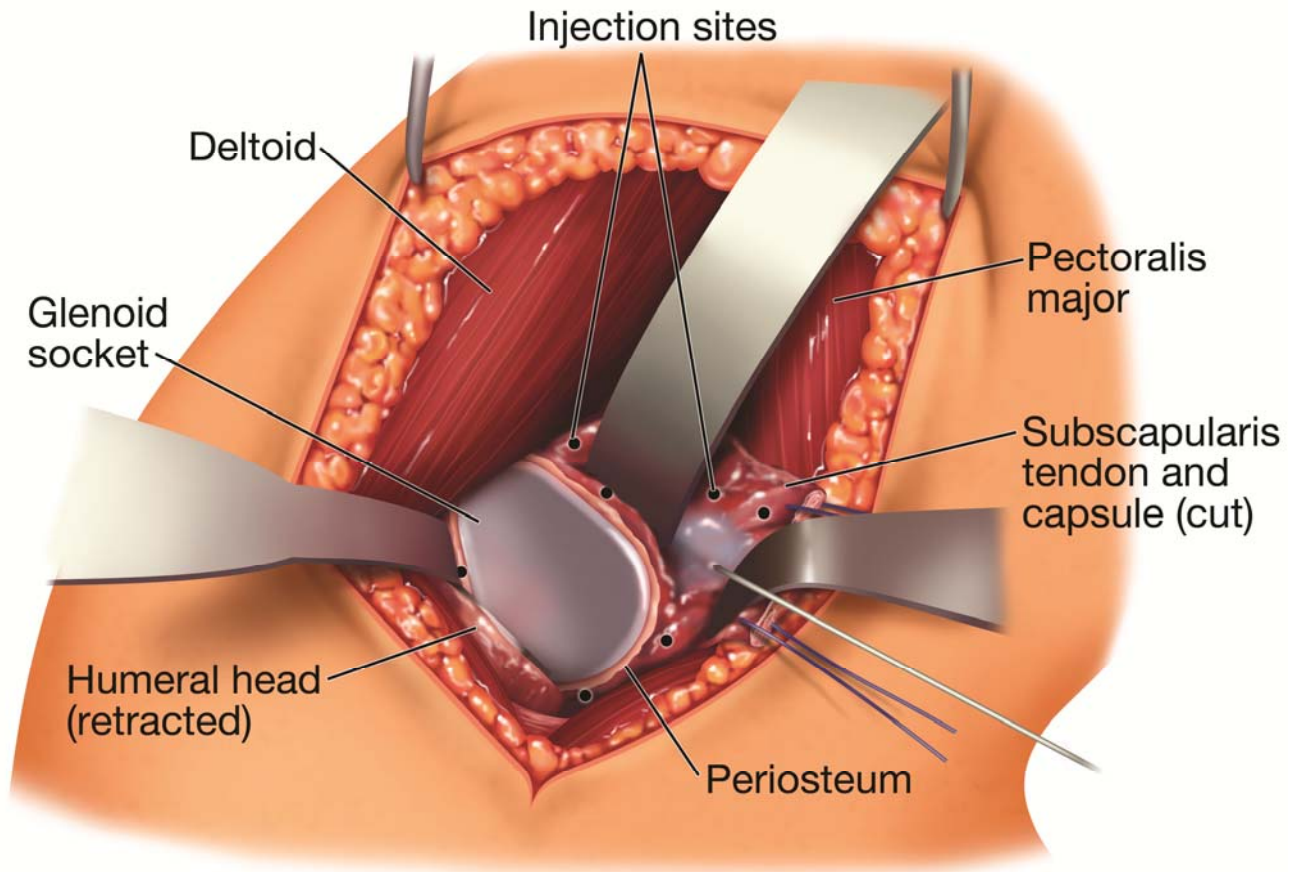
The Best Practices for the Management of Surgical Pain

Infiltration technique for shoulder arthroplasty



Incision for shoulder surgery

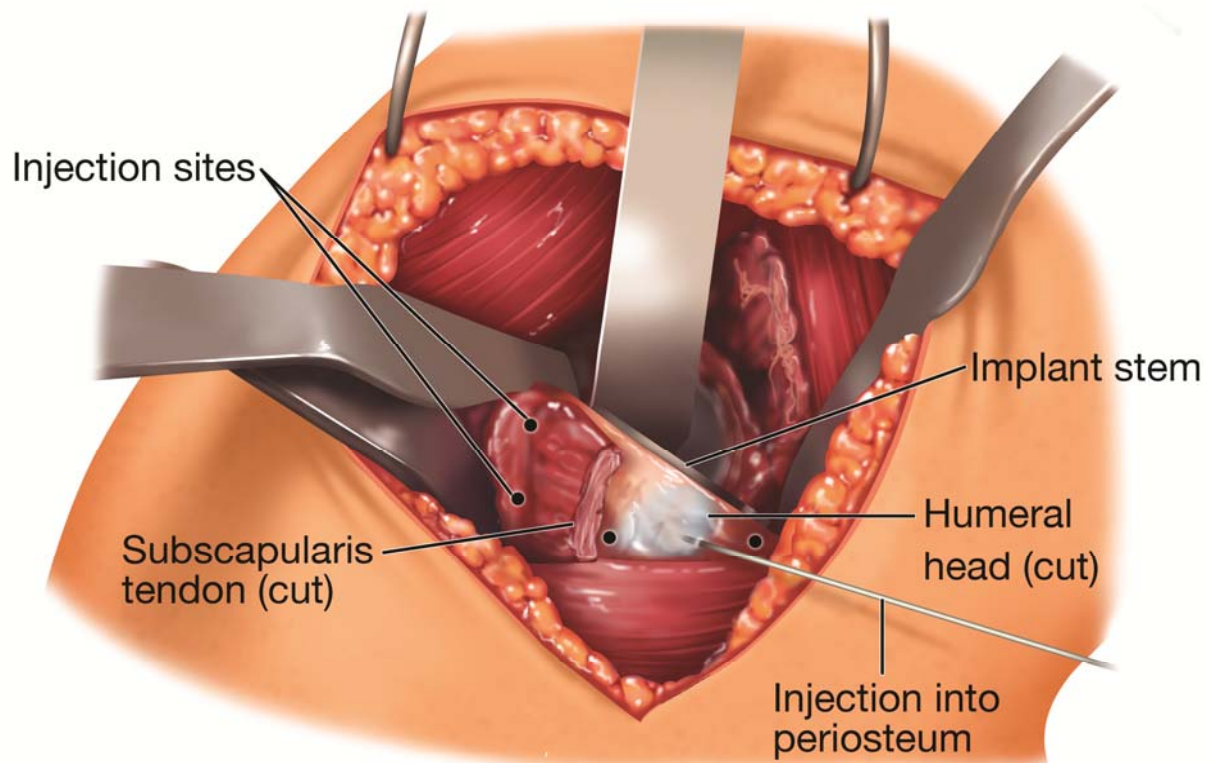
## Infiltration technique for shoulder arthroplasty



Deep infiltration with local anesthetic solution: deep structures around the glenoid, including soft tissue and periosteum.

- indicates insertion of the needle.

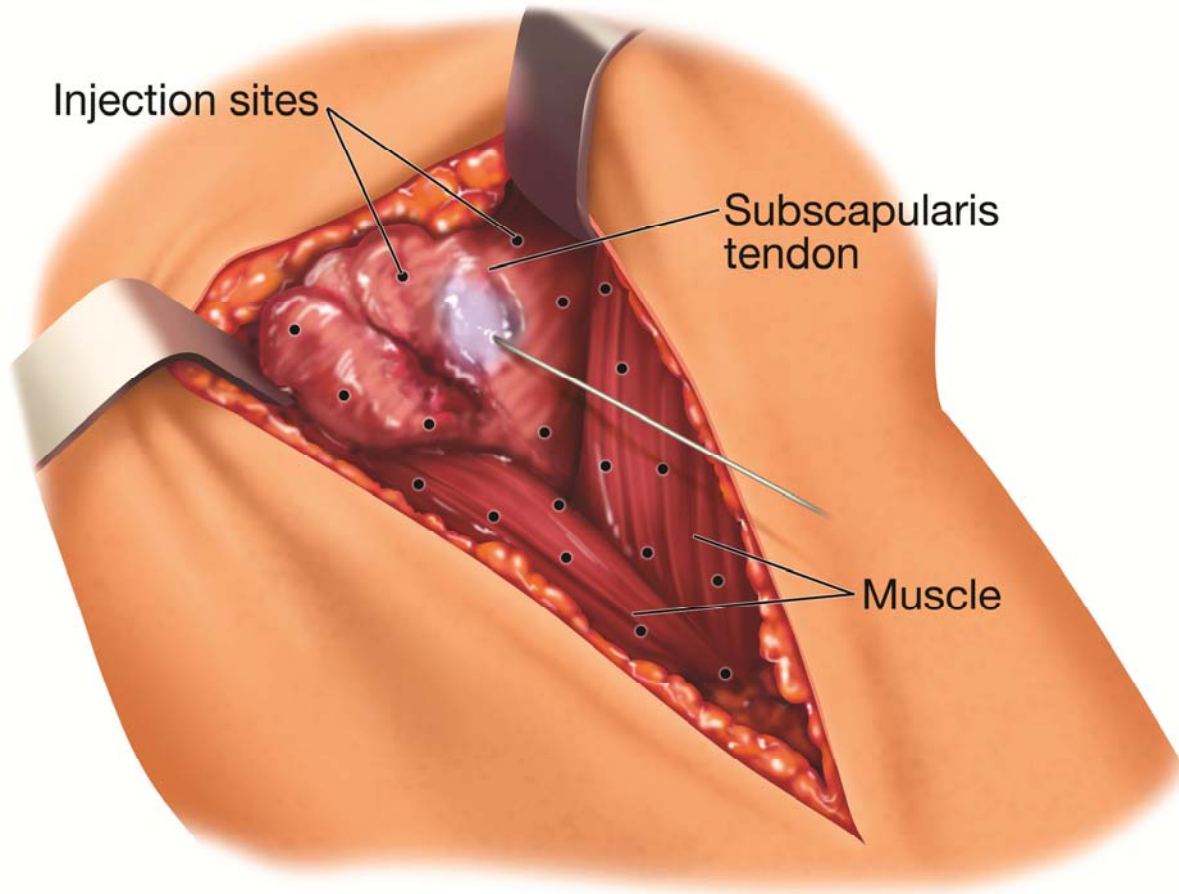
## Infiltration technique for shoulder arthroplasty



Deep infiltration with local anesthetic solution: deep structures around the humerus, including periosteum.

- indicates insertion of the needle.

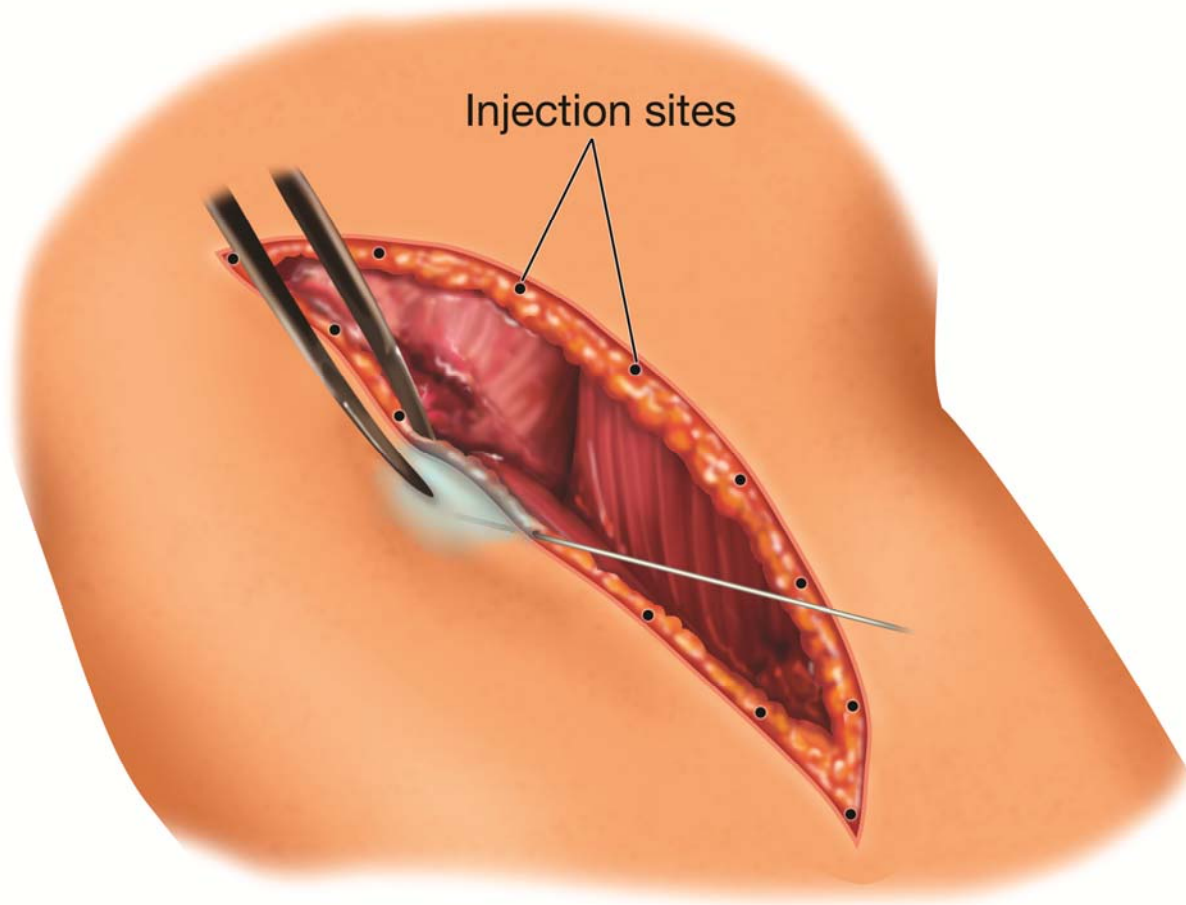
## Infiltration technique for shoulder arthroplasty



Mid-layer infiltration with local anesthetic solution: deltoid, pectoralis, and subscapularis muscle; and subscapularis tendon.

- indicates insertion of the needle.

## Infiltration technique for shoulder arthroplasty



Superficial infiltration with local anesthetic solution: subdermal tissue along the incision.

- indicates insertion of the needle.